CASE REPORT

A Case Report of an Overlap Between Motor Neuron Disease and Parkinson Disease

Abbasher Hussein, Khabab Abbasher, Amira Siddig, Younis Alseddig Hussien Abbashar, Mohammed Abbasher, Ibrahim Hegazy, Abubaker Abbasher

Faculty of Medicine, University of Khartoum, Sudan

Summary

We described a 72-year-old Sudanese patient who had a full-blown picture of Parkinson's disease presenting with tremors and poverty of movement. Examination revealed pill-rolling tremors, cogwheel rigidity, lead-pipe rigidity, and a festinating gait. During the course of the disease, he developed symptoms and signs suggestive of Motor Neuron Disease. The diagnosis of MND was further supported by EMG findings. An overlap syndrome between Parkinson's disease and MND was therefore considered.

Case Report

A. H. M is a 72-year-old Sudanese male. He is not known to have diabetes mellitus or hypertension. During the last two years he used to complain of upper and lower limb weakness, which increased gradually until he became unable to cope with his normal domestic activities. This was not preceded by neck pain, sphincteric disturbance or numbness of extremities. During the course of the disease his elderly son noticed that he had slurred speech and difficulty in swallowing; otherwise there were no symptoms in favour of cranial nerve involvement or increased intracranial pressure. He has no family history of a similar condition, and his past medical history was insignificant.



Figure 1. *Clinical photograph illustrating the patient's posture and limb findings.*

Clinical Examination

He looks unwell. Pulse 80 beats per minute, regular and good volume. Blood pressure was 110/70 mmHg. Examination of the cardiovascular system, chest and abdomen revealed no abnormalities. The abnormalities were confined to the central nervous system, where he is fully conscious, oriented in time, person and place.

Both recent and remote memories were intact, although he was a little bit emotionally labile. He had obvious tongue fasciculation and slight weakness of palatal movement; otherwise there were no symptoms in favour of cranial nerve involvement. There was no neck stiffness. Both upper limbs showed distal muscle wasting (small muscles of the hands) and remarkable fasciculation. The tone was hypertonic in both upper limbs while the power varied from grade four to grade three in the proximal group of muscles and grade two in the distal groups of muscles.

The reflexes were exaggerated. All modalities of sensation were intact including light touch, pin-prick, vibration and position. EMG supported the diagnosis of MND. Coordination could not be demonstrated due to the pronounced weakness of the distal parts of both limbs. Both lower limbs showed wasting, fasciculation, hypertonia and hyperreflexia.

The power varied from grade four in the proximal groups of muscles to grade two in the distal groups of muscles. All modalities of sensation were intact. Both coordination and gait could not be demonstrated due to remarkable weakness of both lower limbs. A clinical diagnosis of motor neuron disease was made and this was supported by EMG findings. During the course of the disease the patient showed parkinsonian features (mask-like facial appearance, pill-rolling tremor, rigidity, hypokinesia and shuffling gait) supporting the diagnosis of Parkinson disease on top of motor neuron disease (overlap).

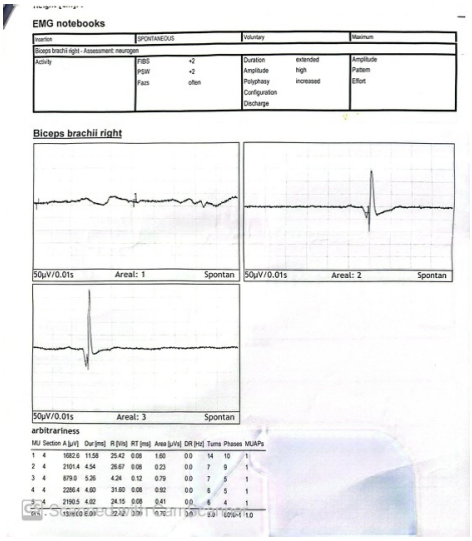

Figure 2. *Additional clinical photograph from the case examination.*

Literature Review

Pathogenesis of MNDs

Motor neuron disease is a progressive degenerative disorder affecting specialized nerve cells called motor neurons that control muscle movement. Motor neurons are vital in controlling the various

activities of the body that involve muscle movement, including walking, running, speaking, swallowing, breathing and gripping. As the disease progresses, these actions become difficult and eventually the person is unable to carry them out at all. The skeletal muscles are voluntarily controlled, such as those in the legs used for walking. These muscles are innervated by a group of nerves called the lower motor neurons, found in the ventral horn of the spinal cord and responsible for all voluntary movements.

The lower motor neurons are activated by the release of glutamate from the upper motor neurons in the brain stem. In motor neuron disease, damage to the ventral horns of the spinal cord leads to atrophy of the ventral roots. Neurons in the frontal and temporal lobes also degenerate. Studies looking at the nerve damage caused by motor neuron disease have revealed the presence of sponge-like deformities called spongiosis, skein-like inclusions and Bunina bodies, as well as the formation of vacuoles. In around 5% of people who suffer from motor neuron disease, defective genes are thought to play a role in contributing to the disease.

A number of genes have been identified that cause the inherited form of this disease, and these include: SOD1, TDP-43, FUS, VCP, C9ORF72, SQSTM1 and Profilin 1.

In motor neuron diseases (MNDs), two sets of motor neurons can be affected: **1)** Upper motor neurons (UMNs), which originate from the primary motor cortex of the cerebrum (precentral gyrus) and possess long axons forming corticospinal and corticobulbar tracts. **2)** Lower motor neurons (LMNs), which originate in the brainstem (cranial nerve motor nuclei), spinal cord (anterior horn cells) and directly innervate skeletal muscles.

They are classified into two categories: **Sporadic MNDs** — amyotrophic lateral sclerosis, primary lateral sclerosis, progressive muscular atrophy, progressive bulbar palsy, pseudobulbar palsy, and monomelic amyotrophy; and **Inherited MNDs** — familial amyotrophic lateral sclerosis.

Parkinson Disease

Parkinson disease is a chronic progressive neurological disease chiefly of later life that is linked to decreased dopamine production in the substantia nigra, and is marked especially by tremor of resting muscles, rigidity, slowness of movement, impaired balance, and a shuffling gait. The etiology of Parkinson disease is still not clear and is still considered idiopathic. Types of Parkinson disease include: Corticobasal Degeneration (CBD), Dementia with Lewy Bodies (DLB), Drug-induced Parkinsonism, Multiple System Atrophy (MSA), Progressive Supranuclear Palsy (PSP), and Vascular (Arteriosclerotic) Parkinsonism. The pathophysiology of Parkinson's disease is death of dopaminergic neurons as a result of changes in biological activity in the brain. There are several proposed mechanisms for neuronal death in PD, though not all of them are well understood.

Five proposed major mechanisms for neuronal death in Parkinson's Disease include protein aggregation in Lewy bodies, disruption of autophagy, changes in cell metabolism or mitochondrial function, neuroinflammation, and blood-brain barrier (BBB) breakdown resulting in vascular leakiness.

Angiogenins

Angiogenin (Ang), also known as ribonuclease 5, is a small 123 amino acid protein that in humans is encoded by the Angiogenin gene. Angiogenin is present in the brain and spinal cord, and is a potent stimulator of new blood vessels through the process of angiogenesis. Angiogenin hydrolyzes cellular RNA, resulting in modulated levels of protein synthesis, and interacts with DNA causing a promoter-like increase in the expression of RNA which protects neurons from cell death. Angiogenin is associated with neurological disease through angiogenesis and through activating gene expression that suppresses apoptosis. Several studies have suggested an increased frequency of variants in the gene encoding angiogenin (ANG) in patients with amyotrophic lateral sclerosis (ALS).

Mutations in this protein have been found in sufferers of PD and ALS and are thought to play a key role in the progression of the condition. Interestingly, a few ALS patients carrying Angiogenin variants also showed signs of Parkinson disease. Furthermore, relatives of ALS patients have an increased risk to develop PD, and the prevalence of concomitant motor neuron disease in PD is higher than expected based on chance occurrence. We therefore consider whether ANG variants could predispose to both ALS and PD.

References

1-Abdelnour-Mallet M, Verschueren A, Guy N, Soriani MH, Chalbi M, Gordon P, et al. Safety of home parenteral nutrition in patients with amyotrophic lateral sclerosis: a French national survey. Amyotrophic Lateral Sclerosis. 2011;12(3):178–184. 2. Aboussouan LS, Khan SU, Meeker DP, Stelmach K, Mitsumoto H. Effect of noninvasive positive-pressure ventilation on survival in amyotrophic lateral sclerosis. Annals of Internal Medicine.1997;127(6):450–453. 3. Abrahams S, Goldstein LH, Al-Chalabi A, Pickering A, Morris RG, Passingham RE, et al. Relation between cognitive dysfunction and pseudobulbar palsy in amyotrophic lateral sclerosis. Journal of Neurology, Neurosurgery and Psychiatry. 1997;62(5):464– 472. 4. Abrahams S, Goldstein LH, Simmons A, Brammer M, Williams SCR, Giampietro V, et al. Word retrieval in amyotrophic lateral sclerosis: a functional magnetic resonance imaging study. Brain.2004;127(Pt 7):1507–1517. 5. Abrahams S, Leigh PN, Goldstein LH. Cognitive change in ALS: a prospective study. Neurology.2005;64(7):1222–1226. 6. Abrahams S, Goldstein LH, Suckling J, Ng V, Simmons A, Chitnis X, et al. Frontotemporal white matter changes in amyotrophic lateral sclerosis. Journal of Neurology. 2005;252(3):321–331. 7. Achille MA, Ogloff JRP. Attitudes toward and desire for assisted suicide among persons with amyotrophic lateral sclerosis. Omega. 2003;48(1):1–21. 8. Adelman EE, Albert SM, Rabkin JG, Del Bene ML, Tider T, O'Sullivan I. Disparities in perceptions of distress and burden in ALS patients and family caregivers. Neurology. 2004;62(10):1766–1770. 9. Adler D, Heritier A-C, Leuchter I, Genton L, Viatte V, Janssens JP, et al. Respiratory failure treated by NIV is not associated with a worst outcome Respiration. 87 during peg insertion in ALS patients. 2014; (6):541–542. 10. Agosta F, Pagani E, Petrolini M, Caputo D, Perini M, Prelle A, et al. Assessment of white matter tract damage in patients with amyotrophic lateral American sclerosis: a diffusion tensor MR imaging tractography study. Journal of Neuroradiology. 31 2010; (8):1457–1461.

11-Gasser T. Genetics of Parkinson's disease. Curr Opin Neurol. 2005 Aug;18(4):363-9.

12-Hardy J, Cai H, Cookson MR, Gwinn-Hardy K, Singleton A. Genetics of Parkinson's disease and parkinsonism. Ann Neurol. 2006 Oct;60(4):389-98.

13-Huang Y, Cheung L, Rowe D, Halliday G. Genetic contributions to Parkinson's disease. Brain Res Brain Res Rev. 2004 Aug;46(1):44-70.

14-Jain S, Wood NW, Healy DG. Molecular genetic pathways in Parkinson's disease: a review. Clin Sci (Lond). 2005 Oct;109(4):355-64.

15-Klein C, Schneider SA, Lang AE. Hereditary parkinsonism: Parkinson disease look-alikes--an algorithm for clinicians to "PARK" genes and beyond. Mov Disord. 2009 Oct 30;24(14):2042-58. doi: 10.1002/mds.22675.

16-Lewthwaite AJ, Nicholl DJ. Genetics of parkinsonism. Curr Neurol Neurosci Rep. 2005 Sep;5(5):397-404.

17-Morris HR. Genetics of Parkinson's disease. Ann Med. 2005;37(2):86-96.

18-Nuytemans K, Theuns J, Cruts M, Van Broeckhoven C. Genetic etiology of Parkinson disease associated with mutations in the SNCA, PARK2, PINK1, PARK7, and LRRK2 genes: a mutation update. Hum Mutat. 2010 Jul;31(7):763-80. doi: 10.1002/humu.21277.

19-Pankratz N, Foroud T. Genetics of Parkinson disease. NeuroRx. 2004 Apr;1(2):235-42.

20-Samii A, Nutt JG, Ransom BR. Parkinson's disease. Lancet. 2004 May 29;363(9423):1783-93.

21-Greenway MJ, Andersen PM, Russ C, Ennis S, Cashman S, Donaghy C, Patterson V, Swingler R, Kieran D, Prehn J, Morrison KE, Green A, Acharya KR, Brown RH, Hardiman O. ANG mutations segregate with familial and 'sporadic' amyotrophic lateral sclerosis. Nat Genet. 2006 Apr;38(4):411-3.

22-Schymick JC, Talbot K, Traynor BJ. Genetics of sporadic amyotrophic lateral sclerosis. Hum Mol Genet. 2007 Oct 15;16 Spec No. 2:R233-42. 23-van Es MA, Diekstra FP, Veldink JH, Baas F, Bourque PR, Schelhaas HJ, Strengman E, Hennekam EA, Lindhout D, Ophoff RA, van den Berg LH. A case of ALS-FTD in a large FALS pedigree with a K17I ANG mutation. Neurology. 2009 Jan 20;72(3):287-8.

24-Hirano A, Malamud N, Elizan TS, Kurland LT. Amyotrophic lateral sclerosis and Parkinsonism-dementia complex on Guam. Further pathologic studies. Arch Neurol. 1966 Jul;15(1):35-51.

25-Majoor-Krakauer D, Ottman R, Johnson WG, Rowland LP. Familial aggregation of amyotrophic lateral sclerosis, dementia, and Parkinson's disease: evidence of shared genetic susceptibility. Neurology. 1994. Oct;44(10):1872-7.

26-Subramanian V, Crabtree B, Acharya KR. Human angiogenin is a neuroprotective factor and amyotrophic lateral sclerosis associated angiogenin variants affect neurite extension/pathfinding and survival of motor neurons. Hum Mol Genet. 2008 Jan 1;17(1):130-49.

27-Elden AC, Kim HJ, Hart MP, Chen-Plotkin AS, Johnson BS, Fang X, Armakola M, Geser F, Greene R, Lu MM, Padmanabhan A, Clay-Falcone D, McCluskey L, Elman L, Juhr D, Gruber PJ, Rüb U, Auburger G, Trojanowski JQ, Lee VM, Van Deerlin VM, Bonini NM, Gitler AD. Ataxin-2 intermediate-length polyglutamine expansions are associated with increased risk for ALS. Nature. 2010 Aug 26;466(7310):1069-75.

28-Payami H, Nutt J, Gancher S, Bird T, McNeal MG, Seltzer WK, Hussey J, Lockhart P, Gwinn- Hardy K, Singleton AA, Singleton AB, Hardy J, Farrer M. SCA2 may present as levodopa- responsive parkinsonism. Mov Disord. 2003 Apr;18(4):425-9.

29-Wu D, Yu W, Kishikawa H, Folkerth RD, Iafrate AJ, Shen Y, Xin W, Sims K, Hu GF. Angiogenin loss-of-function mutations in amyotrophic lateral sclerosis. Ann Neurol. 2007 Dec; 62(6):609-17.

30-Li S, Yu W, Hu GF. Angiogenin inhibits nuclear translocation of apoptosis inducing factor in a Bcl-2-dependent manner. J Cell Physiol. 2011 Jun 15.